Functional connectivity of the right inferior frontal gyrus and orbitofrontal cortex in depression
Supplementary Material

Social Cognitive and Affective Neuroscience (2020) https://doi.org/10.1093/scan/nsaa014

Edmund T. Rolls[1,2,3,#]; Wei Cheng[1,#,*]; Jingnan Du[1,#]; Dongtao Wei[5,#]; Jiang Qiu[4,5,#]; Dan Dai[1,#]; Qunjie Zhou[1,#]; Peng Xie[8,9,10,*]; Jianfeng Feng[1, 2, 12,*]

1. Institute of Science and Technology for Brain-inspired Intelligence, Fudan University, Shanghai, 200433, China
2. Department of Computer Science, University of Warwick, Coventry CV4 7AL, UK
3. Oxford Centre for Computational Neuroscience, Oxford, UK
4. Key Laboratory of Cognition and Personality (SWU), Ministry of Education, Chongqing, China
5. Department of Psychology, Southwest University, Chongqing, China
6. Institute of Neuroscience, Chongqing Medical University, Chongqing, China
7. Chongqing Key Laboratory of Neurobiology, Chongqing, China
8. Department of Neurology, Yongchuan Hospital of Chongqing Medical University, Chongqing 402160, China
9. School of Mathematical Sciences, School of Life Science and the Collaborative Innovation Center for Brain Science, Fudan University, Shanghai, 200433, PR China

[#] These authors contributed equally to this work.

* Corresponding authors

Participants

There were 282 patients with a diagnosis of major depression, and 254 controls. The patients were from Xinan (First Affiliated Hospital of Chongqing Medical School in Chongqing, China). All participants were diagnosed according to the Diagnostic and Statistical Manual of Mental Disorder-IV criteria for major depressive disorder. Depression severity and symptomatology were evaluated by the Hamilton Depression Rating Scale (HAMD, 17 items) (Hamilton, 1960) and the Beck Depression Inventory (BDI) (Beck and Beamesderfer, 1974). Table S1 provides a summary of the demographic information and the psychiatric diagnosis (showing how they were diagnosed) of the participants. The data collection was approved by the local ethical review committees, was in accordance with the Code of Ethics of the World Medical Association (Declaration of Helsinki), and informed consent was obtained. This is a subset of patients from a previous functional connectivity investigation that can now be analyzed further (Cheng *et al.*, 2016), and the analysis used here is completely different and novel in its application to depression, in the ways set out in the paper. With respect to age and sex, Table S1 shows that there were no significant differences in the age and sex of the depressed groups and the controls. Further, the effects of age and sex were regressed out in all analyses. 125 of the patients were not receiving medication at the time of the neuroimaging. The patients receiving medication were different participants. The medication for these patients consisted in most cases of selective serotonin reuptake inhibitors (SSRIs) including fluoxetine, paroxetine, sertraline, citalopram and escitalopram; or serotonin-norepinephrine reuptake inhibitors (SNRIs) such as venflaxine, or a tetracyclic antidepressant such as mirtazepine. Further details follow.

Patients with MDD were recruited from the outpatient department of the First Affiliated Hospital of Chongqing Medical School in Chongqing, China. All were diagnosed according to the Structured Clinical Interview for DSM-IV, by independent assessments of two psychiatrists. They were also assessed for disease severity using the Hamilton Depression Rating Scale (HAMD) (Hamilton, 1960) and Beck Depression Inventory (BDI), illness duration and the medication status of the patients. Before the investigation, we excluded individuals who were not suitable for MRI scanning by interview and by the self-reported checklist. The MRI related exclusion criteria include claustrophobia, metallic implants, Meniere's Syndrome and a history of fainting within the previous half year. Exclusion criteria for both groups were as follows: current psychiatric disorders (except for MDD) and neurological disorders; substance abuse; and stroke or serious encephalopathy. Of note, all of the subjects in the control group did not meet DSM-IV criteria for any psychiatric disorders and did not use any drugs that could affect brain function. This study was approved by the Research Ethics Committee of the Brain Imaging Center of Southwest University and First Affiliated Hospital of Chongqing Medical School. Informed written consent was obtained from each subject. This study was conducted in accordance with the Helsinki Declaration as revised in 1989.

Image Acquisition

All images were acquired on a 3.0-T Siemens Trio MRI scanner using a 16-channel whole-brain coil (Siemens Medical, Erlangen, Germany). High- resolution T1-weighted 3D images were acquired using a magnetization-prepared rapid gradient echo (MPRAGE) sequence (echo time (TE) = 2.52 ms; repetition time (TR) = 1900 ms; inversion time (TI) = 900 ms; flip angle = 9 degrees; slices = 176; thickness = 1.0 mm; resolution matrix = 256×256; voxel size = 1×1×1 mm3). For each participant, 242 functional images were acquired with a gradient echo type Echo Planar Imaging (EPI) sequence (echo time (TE) = 30 ms; repetition time (TR) = 2000 ms; flip angle = 90 degrees; slices = 32; slice thickness = 3.0 mm; slice gap = 1 mm; resolution matrix = 64×64; voxel size 3.4×3.4×3mm^3). Data for resting state functional connectivity analysis were collected in an 8 min period in which the participants were awake in the scanner not performing a task using a standard protocol in which the participants were asked to look at a white fixation point on a dark background. All participants performed this during the fMRI imaging as confirmed by the participants after the session.

Table S1. A summary of the demographic information and the psychiatric diagnosis in the present study.

Group	Age (years)	Sex (male/female)	Education (years)	Medication (yes / no)	HAMD	BDI	Duration of illness	First episode (yes / no)	Mean FD
Healthy	39.65 ± 15.80	166 / 88	13.01 ± 3.89	/	/	/	/	/	0.133 ±0.063
Patient	38.74 ± 13.65	183 / 99	11.91 ± 3.58	157 / 125	20.8 ± 5.87	20.42 ± 9.33	4.16 ± 5.51	209 / 49	0.125 ± 0.054
Statistic (t / p) or (chi-square / p)	0.719 / 0.472	0.013 / 0.911	3.41 / 6.9e-4	/	/	/	/	/	1.729 / 0.084
Unmedicated patient	37.60 ± 13.12	84 / 41	12.07 ± 3.72	125 / 0	22.22 ± 4.39	22.51 ± 8.16	2.91 ± 4.44	111 / 14	0.120 ± 0.053
Medicated patient	39.64 ± 14.03	99 / 58	11.78 ± 3.48	0 / 157	19.42 ± 6.73	18.43 ± 9.95	5.33 ± 6.13	98 / 35	0.129 ± 0.054
Statistic (t / p) or (chi-square / p)	-1.250 / 0.212	0.524 / 0.469	0.673 / 0.501	/	3.907 / 1.2e-4	3.520 / 5.1e-4	-3.539 / 4.8e-4	9.570 / 0.002	-1.268 / 0.206

Values are n or mean ± SD.

Note: The difference between patients and controls for continuous variables was assessed by a two-sample t-test and the difference for the binary variable (gender) was assessed by a chi-square test.

Table S2a. The differences in functional connectivity in unmedicated patients with depression of the voxels in the brain areas shown in the columns with other brain areas (shown in the rows). This is the number of voxels found with p<0.05 FDR. The names are from the AAL2 atlas (Rolls *et al.*, 2015).

Lateral orbitofrontal cortex					**Medial orbitofrontal cortex**				
Region	**Change pattern**	**# voxels**	**Peak value**	**MNI cordinates**	**Region**	**Change pattern**	**# voxels**	**Peak value**	**MNI cordinates**
Precuneus	Higher	357	190.83	[3,-54,36]	Rectus	Higher	375	1027.60	[-6,39,-27]
	Lower	0	0.00	[90,-126,-72]		Lower	139	-567.75	[15,30,-21]
Frontal_Inf_Orb_2	Higher	101	2083.53	[33,33,-12]	Precuneus	Higher	343	104.25	[3,-54,36]
	Lower	8	-340.19	[-21,27,-12]		Lower	0	0.00	[90,-126,-72]
Cingulate_Post	Higher	94	95.25	[6,-54,30]	Orbitofrontal Cortex Med	Higher	124	712.78	[-9,36,-27]
	Lower	0	0.00	[90,-126,-72]		Lower	167	-536.07	[18,30,-21]
Supp_Motor_Area	Higher	0	0.00	[90,-126,-72]	Orbitofrontal Cortex Post	Higher	142	2075.34	[36,33,-15]
	Lower	83	-13.49	[0,15,54]		Lower	88	-412.80	[-21,27,-15]
Frontal_Med_Orb	Higher	64	34.76	[0,51,-15]	Frontal_Mid_2	Higher	181	564.71	[42,21,33]
	Lower	0	0.00	[90,-126,-72]		Lower	12	-8.46	[-39,36,42]
Frontal_Mid_2	Higher	52	126.82	[36,24,21]	Temporal_Inf	Higher	0	0.00	[90,-126,-72]
	Lower	0	0.00	[90,-126,-72]		Lower	185	-274.81	[-39,-12,-39]
Orbitofrontal Cortex Lat	Higher	49	927.69	[42,36,-18]	Frontal_Sup_2	Higher	162	262.54	[15,45,42]
	Lower	3	-8.31	[-48,33,-15]		Lower	11	-25.30	[-15,0,69]
Calcarine	Higher	37	40.67	[3,-60,18]	Orbitofrontal Cortex Ant	Higher	63	1644.28	[36,36,-15]
	Lower	0	0.00	[90,-126,-72]		Lower	105	-209.93	[-18,33,-15]
Angular	Higher	32	52.94	[-39,-57,27]	Frontal_Sup_Medial	Higher	132	205.92	[15,45,45]
	Lower	0	0.00	[90,-126,-72]		Lower	3	-4.37	[12,66,27]
Frontal_Sup_Medial	Higher	21	43.23	[-3,39,42]	Caudate	Higher	109	149.84	[21,18,6]
	Lower	8	-8.37	[-3,30,45]		Lower	18	-76.40	[15,24,-3]
Cingulate_Mid	Higher	27	123.72	[3,-51,33]	Temporal_Pole_Mid	Higher	0	0.00	[90,-126,-72]
	Lower	0	0.00	[90,-126,-72]		Lower	113	-413.75	[24,6,-36]
Cingulate_Ant	Higher	19	42.81	[-12,45,-3]	ParaHippocampal	Higher	0	0.00	[90,-126,-72]
	Lower	0	0.00	[90,-126,-72]		Lower	97	-609.82	[24,3,-30]
Precentral	Higher	17	39.31	[45,3,39]	Cingulate_Post	Higher	90	91.09	[-6,-51,27]
	Lower	0	0.00	[90,-126,-72]		Lower	0	0.00	[90,-126,-72]
Temporal_Inf	Higher	0	0.00	[90,-126,-72]	Supp_Motor_Area	Higher	0	0.00	[90,-126,-72]
	Lower	12	-18.09	[-42,0,-36]		Lower	73	-117.26	[-12,0,63]
Cuneus	Higher	11	30.67	[0,-66,24]	Fusiform	Higher	0	0.00	[90,-126,-72]
	Lower	0	0.00	[90,-126,-72]		Lower	72	-243.97	[-36,-12,-42]
Frontal_Sup_2	Higher	2	4.21	[-24,39,27]	Frontal_Med_Orb	Higher	68	82.54	[6,51,-6]
	Lower	4	-4.42	[-15,0,69]		Lower	2	-4.17	[6,24,-15]
Occipital_Mid	Higher	3	21.72	[-33,-63,30]	Calcarine	Higher	59	84.05	[3,-60,18]
	Lower	0	0.00	[90,-126,-72]		Lower	0	0.00	[90,-126,-72]
Hippocampus	Higher	2	8.30	[-24,-21,-15]	Cingulate_Ant	Higher	51	115.58	[12,42,24]
	Lower	0	0.00	[90,-126,-72]		Lower	0	0.00	[90,-126,-72]
Lingual	Higher	2	16.71	[9,-42,6]	Postcentral	Higher	1	8.61	[30,-42,75]
	Lower	0	0.00	[90,-126,-72]		Lower	48	-34.26	[-63,-9,21]
Parietal_Sup	Higher	2	4.21	[-24,-72,60]	Cingulate_Mid	Higher	40	107.76	[3,-51,33]
	Lower	0	0.00	[90,-126,-72]		Lower	8	-33.74	[-9,-9,48]

Table S2b. The differences in functional connectivity in in unmedicated patients with depression of the voxels in the brain areas shown (Inferior Frontal Gyrus pars triangularis and pars opercularis) in the columns with other brain areas (shown in the rows). This is the number of voxels found with p<0.05 FDR.

IFGtri					IFGoperc				
Region	**Change pattern**	**# voxels**	**Peak value**	**MNI cordinates**	**Region**	**Change pattern**	**# voxels**	**Peak value**	**MNI coordinates**
Precentral	Higher	1175	229.72	[-54,-63,18]	Temporal_Mid	Higher	1159	409.01	[54,-3,-24]
	Lower	0	0	[90,-126,-72]		Lower	0	0.00	[90,-126,-72]
Frontal_Sup_2	Higher	961	197.54	[-6,45,18]	Precuneus	Higher	799	375.89	[-3,-54,33]
	Lower	2	-4.16	[12,33,60]		Lower	0	0.00	[90,-126,-72]
Frontal_Mid_2	Higher	872	170.69	[-15,54,9]	Frontal_Sup_Medial	Higher	527	197.01	[15,45,6]
	Lower	27	-38.37	[-18,-3,54]		Lower	0	0.00	[90,-126,-72]
Frontal_Inf_Oper	Higher	617	164.38	[-3,-57,33]	Frontal_Inf_Oper	Higher	423	13997.5	[39,15,30]
	Lower	1	-4.09	[9,-60,51]		Lower	5	-8.24	[-33,12,30]
Frontal_Inf_Tri	Higher	460	21272.47	[36,15,27]	Frontal_Sup_2	Higher	322	137.72	[-15,54,9]
	Lower	34	-114.83	[-42,45,12]		Lower	0	0.00	[90,-126,-72]
Frontal_Inf_Orb_2	Higher	390	164.28	[-57,-9,-36]	Angular	Higher	248	366.28	[-45,-69,27]
	Lower	7	-16.94	[-45,-21,-30]		Lower	0	0.00	[90,-126,-72]
Rolandic_Oper	Higher	387	290.16	[-45,-69,27]	Temporal_Inf	Higher	215	276.03	[-60,-9,-27]
	Lower	0	0	[90,-126,-72]		Lower	0	0.00	[90,-126,-72]
Supp_Motor_Area	Higher	342	146.58	[0,57,-3]	Temporal_Pole_Sup	Higher	214	421.37	[-48,9,-24]
	Lower	0	0	[90,-126,-72]		Lower	0	0.00	[90,-126,-72]
Olfactory	Higher	334	168.66	[-12,45,0]	Frontal_Med_Orb	Higher	207	323.99	[0,51,-15]
	Lower	0	0	[90,-126,-72]		Lower	0	0.00	[90,-126,-72]
Frontal_Sup_Medial	Higher	226	312.86	[42,-39,57]	Cingulate_Post	Higher	185	382.13	[0,-54,30]
	Lower	0	0	[90,-126,-72]		Lower	0	0.00	[90,-126,-72]
Frontal_Med_Orb	Higher	221	137.27	[-6,-48,33]	Cingulate_Ant	Higher	181	153.79	[15,42,6]
	Lower	0	0	[90,-126,-72]		Lower	0	0.00	[90,-126,-72]
Rectus	Higher	208	177.94	[-48,9,-21]	Cingulate_Mid	Higher	178	286.61	[-6,-48,33]
	Lower	0	0	[90,-126,-72]		Lower	0	0.00	[90,-126,-72]
Oorbitofrontal Cortex Med	Higher	203	144.73	[-42,15,-30]	Temporal_Pole_Mid	Higher	130	392.01	[-42,15,-30]
	Lower	0	0	[90,-126,-72]		Lower	1	-4.15	[-18,6,-36]
Orbitofrontal Cortex Ant	Higher	182	168.17	[-3,-51,30]	Calcarine	Higher	84	214.59	[3,-60,18]
	Lower	0	0	[90,-126,-72]		Lower	0	0.00	[90,-126,-72]
Orbitofrontal Cortex Post	Higher	156	115.89	[-57,-57,24]	Hippocampus	Higher	83	288.75	[33,-6,-21]
	Lower	0	0	[90,-126,-72]		Lower	0	0.00	[90,-126,-72]
Orbitofrontal Cortex Lat	Higher	142	124.09	[15,0,69]	Postcentral	Higher	76	103.17	[42,-39,57]
	Lower	2	-25.66	[15,6,51]		Lower	0	0.00	[90,-126,-72]
Insula	Higher	141	95.42	[54,-57,21]	Temporal_Sup	Higher	69	179.78	[-57,0,-15]
	Lower	0	0	[90,-126,-72]		Lower	0	0.00	[90,-126,-72]
Cingulate_Ant	Higher	139	108.59	[42,30,21]	Frontal_Mid_2	Higher	59	187.03	[-33,27,21]
	Lower	0	0	[90,-126,-72]		Lower	0	0.00	[90,-126,-72]
Cingulate_Mid	Higher	76	60.41	[33,-9,-21]	Cuneus	Higher	58	192.40	[-3,-66,21]
	Lower	0	0	[90,-126,-72]		Lower	0	0.00	[90,-126,-72]
Cingulate_Post	Higher	60	87.51	[-3,-66,24]	Supp_Motor_Area	Higher	46	47.31	[-9,-9,75]
	Lower	0	0	[90,-126,-72]		Lower	0	0.00	[90,-126,-72]

Table S3. The anatomical regions defined in each hemisphere and their label in the automated anatomical labelling atlas AAL2 (Rolls *et al.*, 2015). Column 4 provides a set of possible abbreviations for the anatomical descriptions.

NO.	ANATOMICAL DESCRIPTION	LABEL aal2.nii.gz	POSSIBLE ABBREVIATION
1,2	Precentral gyrus	Precentral	PreCG
3, 4	Superior frontal gyrus, dorsolateral	Frontal_Sup	SFG
5, 6	Middle frontal gyrus	Frontal_Mid	MFG
7, 8	Inferior frontal gyrus, opercular part	Frontal_Inf_Oper	IFGoperc
9, 10	Inferior frontal gyrus, triangular part	Frontal_Inf_Tri	IFGtriang
11, 12	IFG pars orbitalis,	Frontal_Inf_Orb	IFGorb
13, 14	Rolandic operculum	Rolandic_Oper	ROL
15, 16	Supplementary motor area	Supp_Motor_Area	SMA
17, 18	Olfactory cortex	Olfactory	OLF
19, 20	Superior frontal gyrus, medial	Frontal_Sup_Med	SFGmedial
21, 22	Superior frontal gyrus, medial orbital	Frontal_Med_Orb	PFCventmed
23, 24	Gyrus rectus	Rectus	REC
25, 26	Medial orbital gyrus	OFCmed	OFCmed
27, 28	Anterior orbital gyrus	OFCant	OFCant
29, 30	Posterior orbital gyrus	OFCpost	OFCpost
31, 32	Lateral orbital gyrus	OFClat	OFClat
33, 34	Insula	Insula	INS
35, 36	Anterior cingulate & paracingulate gyri	Cingulate_Ant	ACC
37, 38	Middle cingulate & paracingulate gyri	Cingulate_Mid	MCC
39, 40	Posterior cingulate gyrus	Cingulate_Post	PCC
41, 42	Hippocampus	Hippocampus	HIP
43, 44	Parahippocampal gyrus	ParaHippocampal	PHG
45, 46	Amygdala	Amygdala	AMYG
47, 48	Calcarine fissure and surrounding cortex	Calcarine	CAL
49, 50	Cuneus	Cuneus	CUN
51, 52	Lingual gyrus	Lingual	LING
53, 54	Superior occipital gyrus	Occipital_Sup	SOG
55, 56	Middle occipital gyrus	Occipital_Mid	MOG
57, 58	Inferior occipital gyrus	Occipital_Inf	IOG
59, 60	Fusiform gyrus	Fusiform	FFG
61, 62	Postcentral gyrus	Postcentral	PoCG
63, 64	Superior parietal gyrus	Parietal_Sup	SPG
65, 66	Inferior parietal gyrus, excluding supramarginal and angular gyri	Parietal_Inf	IPG
67, 68	SupraMarginal gyrus	SupraMarginal	SMG
69, 70	Angular gyrus	Angular	ANG
71, 72	Precuneus	Precuneus	PCUN
73, 74	Paracentral lobule	Paracentral_Lobule	PCL
75, 76	Caudate nucleus	Caudate	CAU
77, 78	Lenticular nucleus, Putamen	Putamen	PUT
79, 80	Lenticular nucleus, Pallidum	Pallidum	PAL
81, 82	Thalamus	Thalamus	THA
83, 84	Heschl's gyrus	Heschl	HES
85, 86	Superior temporal gyrus	Temporal_Sup	STG
87, 88	Temporal pole: superior temporal gyrus	Temporal_Pole_Sup	TPOsup
89, 90	Middle temporal gyrus	Temporal_Mid	MTG
91, 92	Temporal pole: middle temporal gyrus	Temporal_Pole_Mid	TPOmid
93, 94	Inferior temporal gyrus	Temporal_Inf	ITG

Figure S1. The regions of interest within which the functional connectivity of voxels was analyzed in this investigation. The medial orbitofrontal cortex regions (purple) include from the automated anatomical labelling atlas 2 (Rolls *et al.*, 2015) gyrus rectus, OFCmed, OFCant, and OFCpost. The lateral orbitofrontal cortex (red, approximately BA 47/12) includes OFClat and FrontalInfOrb, with these names shown in Table S3 from the AAL2 atlas. The inferior frontal cortex pars triangularis (approximately BA 45) is in blue, and the inferior frontal cortex pars opercularis (approximately BA 44) is in green.

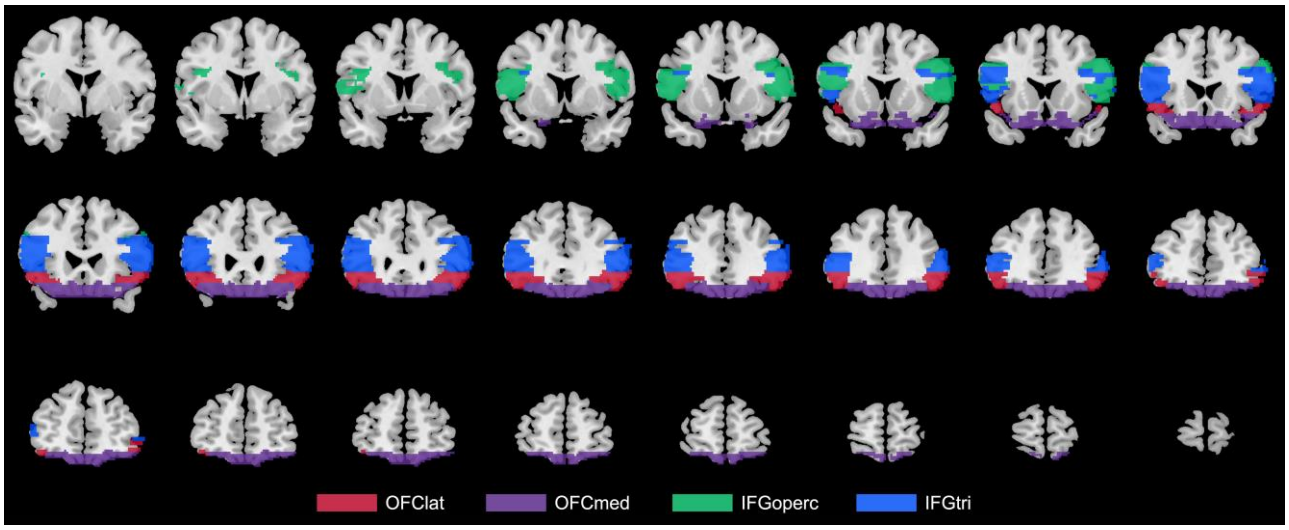

Figure S2. Anatomical location of voxels with significantly higher (A) and lower (B) functional connectivity with the inferior frontal gyrus and the orbitofrontal cortex in non-medicated depression (patients - controls) obtained from the voxel-based Association Study. Blue indicates voxels with lower functional connectivity in depressed patients, and red/yellow indicates voxels with higher functional connectivity. In this and in all other Figures, the level of statistical significance for the difference in functional connectivity for any voxel after correction for multiple comparisons was p<0.05 FDR.

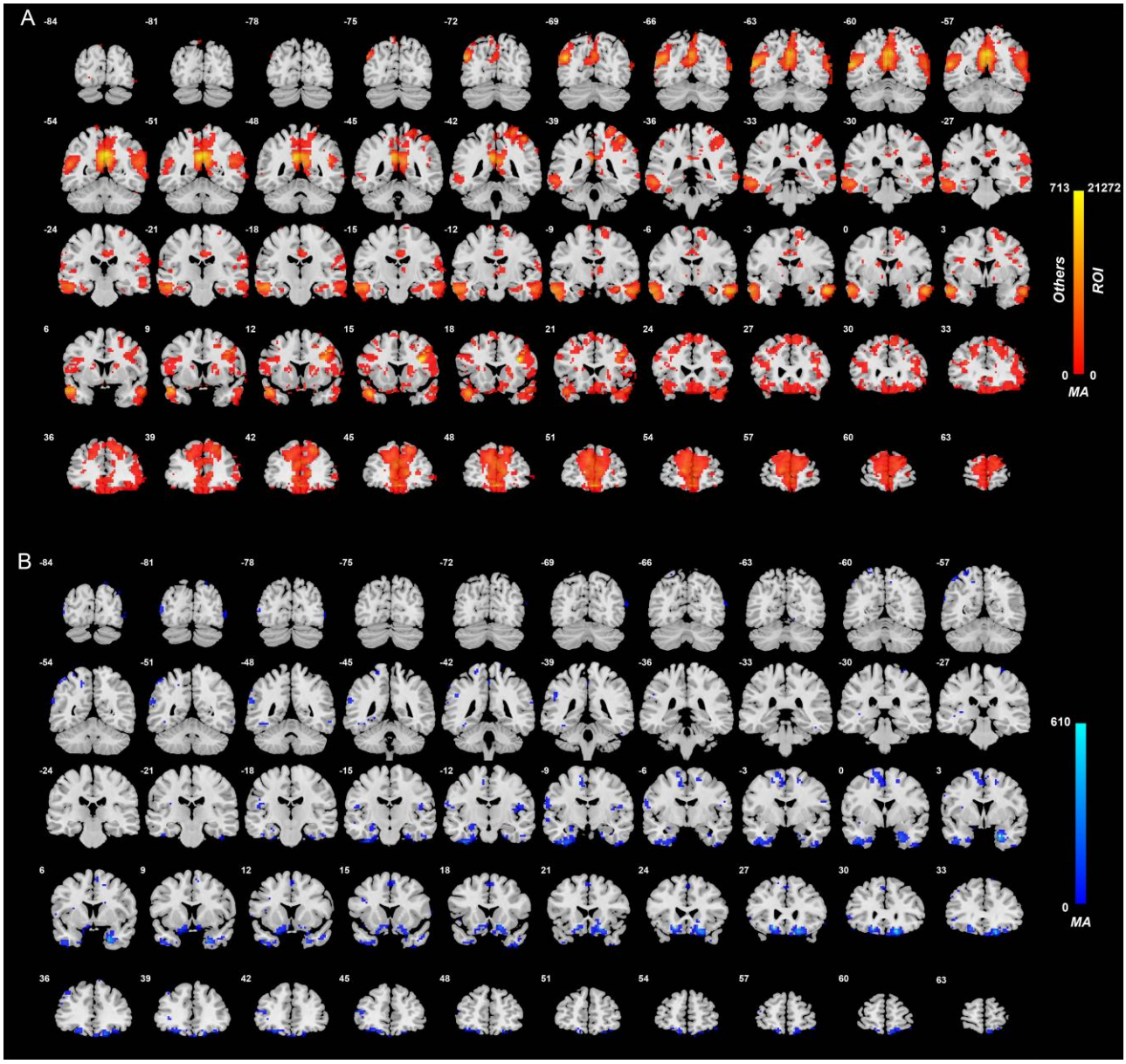

Figure S3. Anatomical location of voxels with significantly higher (A) and lower (B) functional connectivity with the inferior frontal gyrus and the orbitofrontal cortex in medicated patients - non-medicated patients obtained from the voxel-based Association Study. Blue indicates voxels with lower functional connectivity in medicated depressed patients, and red/yellow indicates voxels with higher functional connectivity in medicated depressed patients.

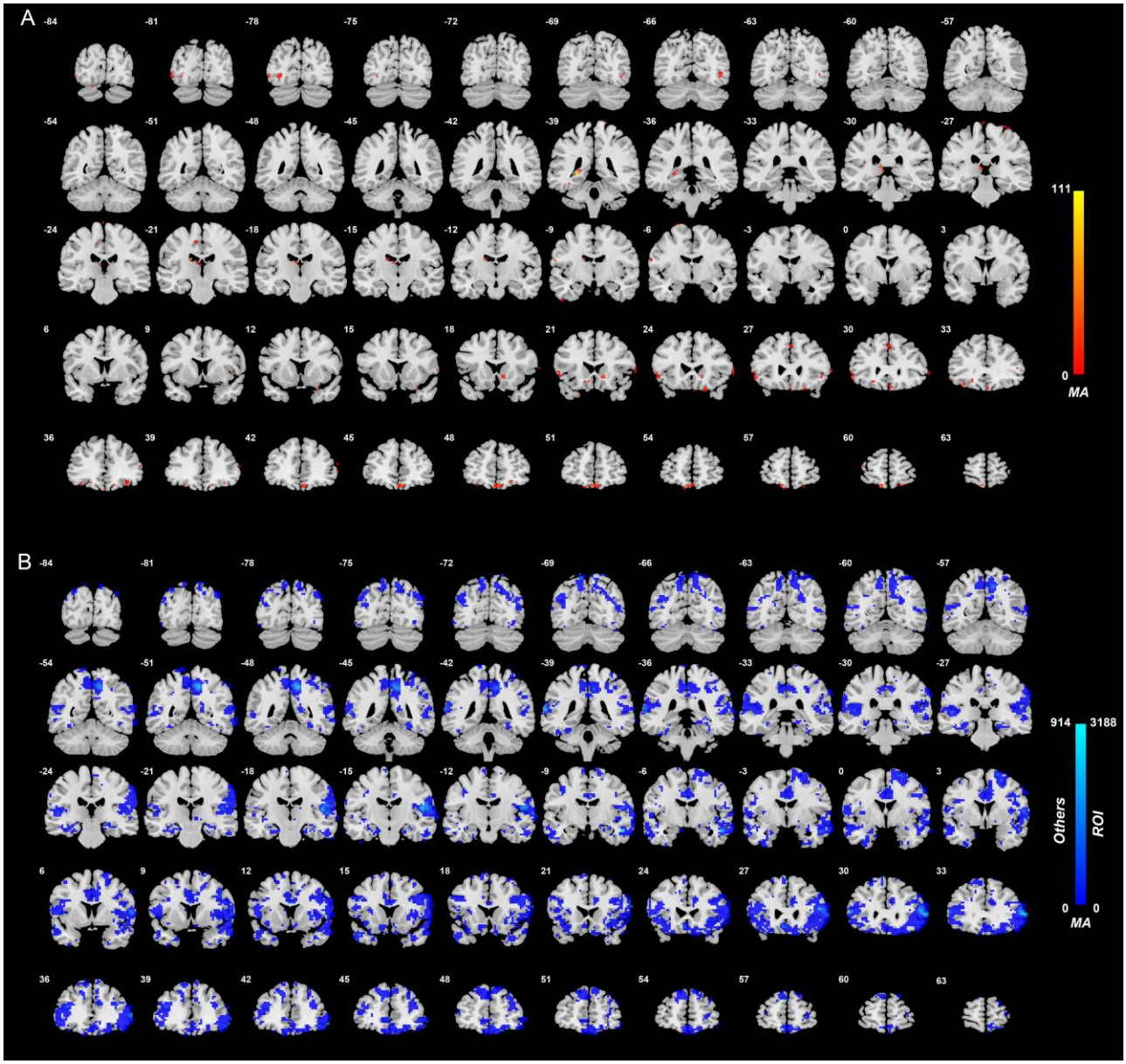

Figure S4. Anatomical location of voxels with significantly higher (A) and lower (B) functional connectivity with the lateral orbitofrontal cortex areas in medicated patients - non-medicated patients obtained from the voxel-based Association Study. Blue indicates voxels with lower functional connectivity in medicated than medicated depressed patients, and red/yellow indicates voxels with higher functional connectivity in medicated than medicated depressed patients.

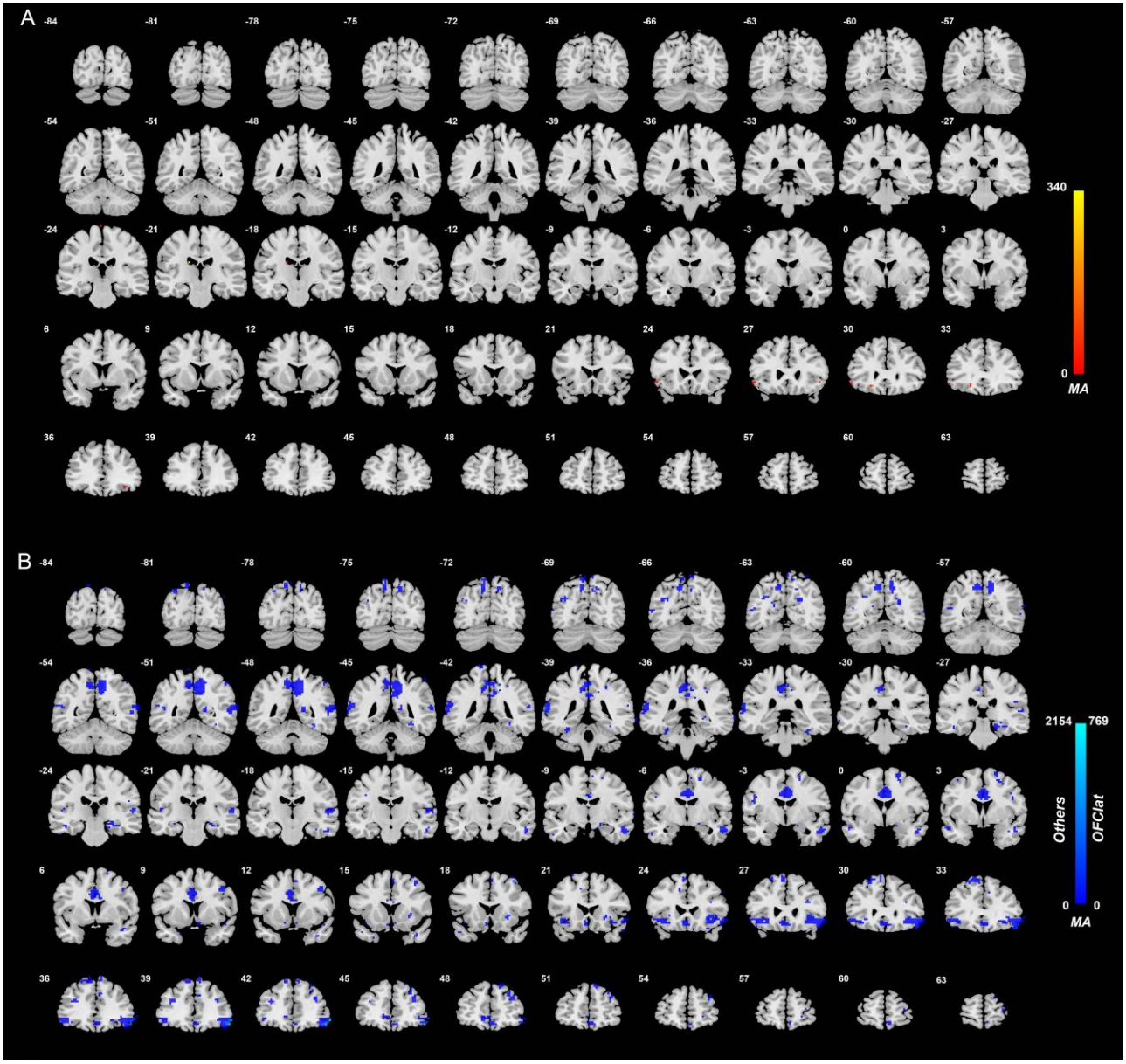

Figure S5. Anatomical location of voxels with significantly higher (A) and lower (B) functional connectivity with the medial orbitofrontal cortex areas in medicated patients - non-medicated patients obtained from the voxel-based Association Study. Blue indicates voxels with lower functional connectivity in medicated depressed patients, and red/yellow indicates voxels with higher functional connectivity in medicated depressed patients.

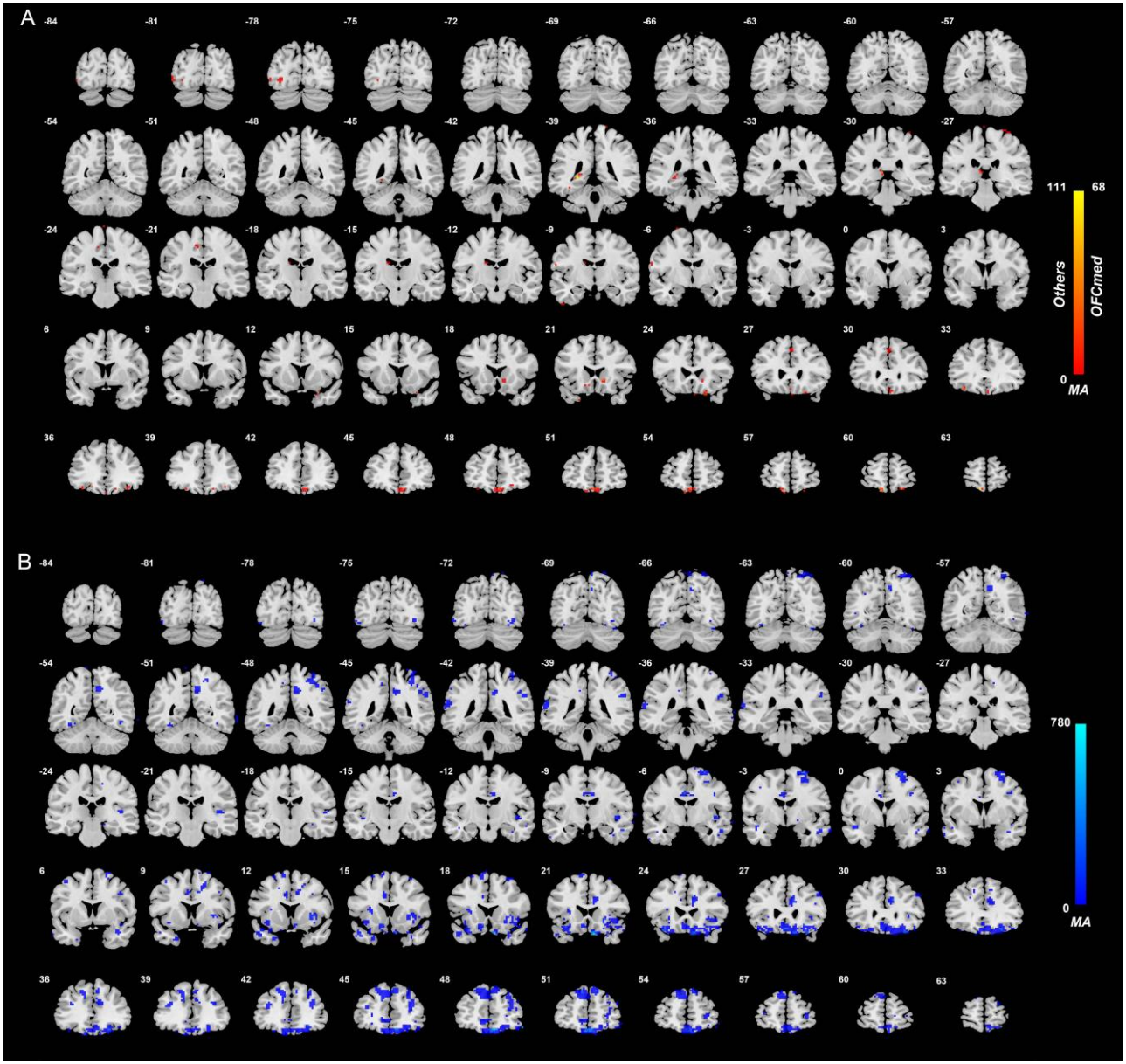

Figure S6. Anatomical location of voxels with significantly higher (A) and lower (B) functional connectivity of the inferior frontal gyrus (triangular part) in medicated patients - non-medicated patients obtained from the voxel-based Association Study. Blue indicates voxels with lower functional connectivity in medicated depressed patients, and red/yellow indicates voxels with higher functional connectivity in medicated depressed patients. Medication was associated with lower functional connectivity with the precuneus, motor cortical areas, the temporal cortex, and the supramarginal gyrus.

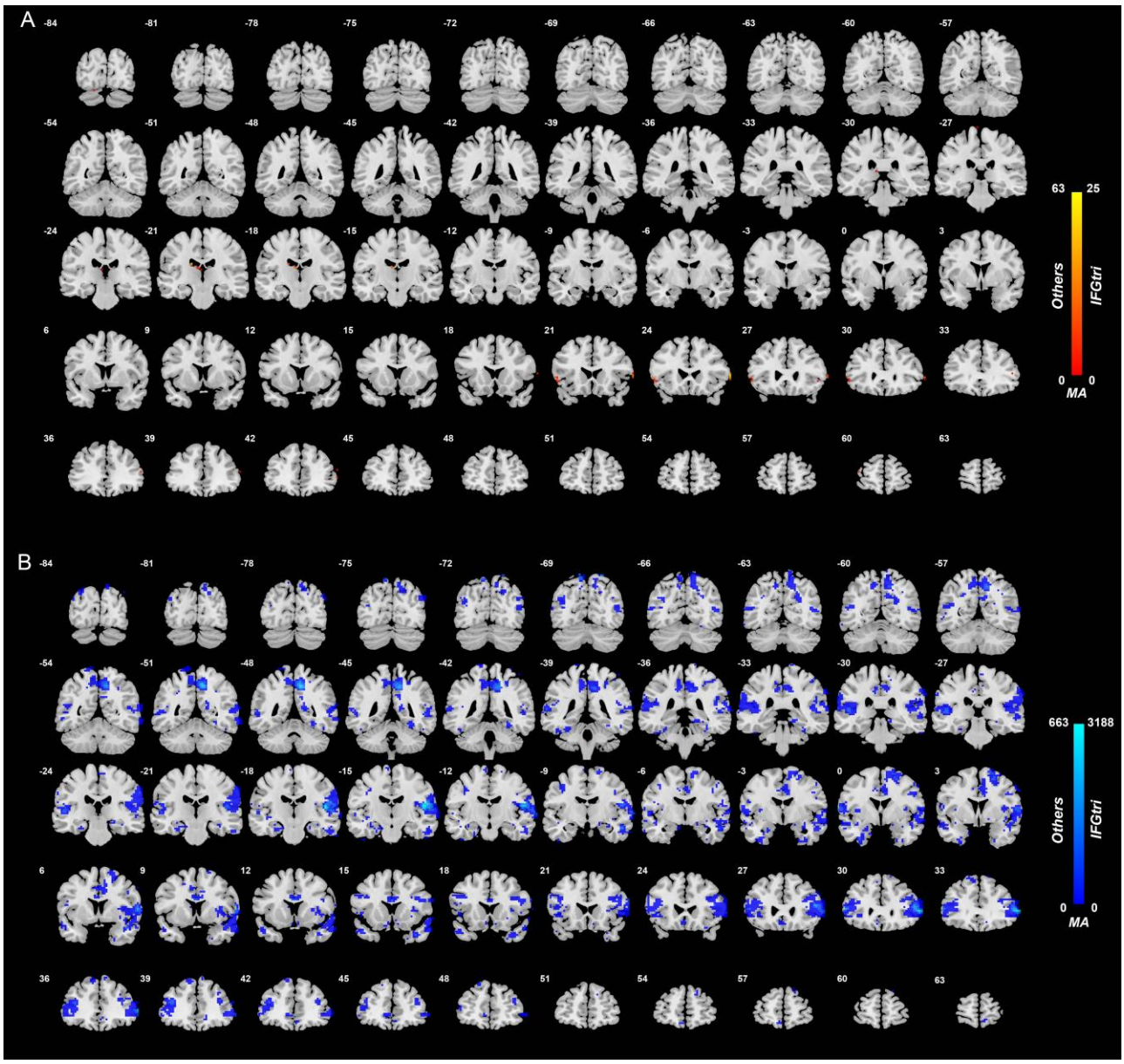

Figure S7. Anatomical location of voxels with significantly higher (A) and lower (B) functional connectivity with the inferior frontal gyrus (opercular part) in medicated patients - non-medicated patients obtained from the voxel-based Association Study. Blue indicates voxels with lower functional connectivity in medicated depressed patients, and red/yellow indicates voxels with higher functional connectivity in medicated depressed patients.

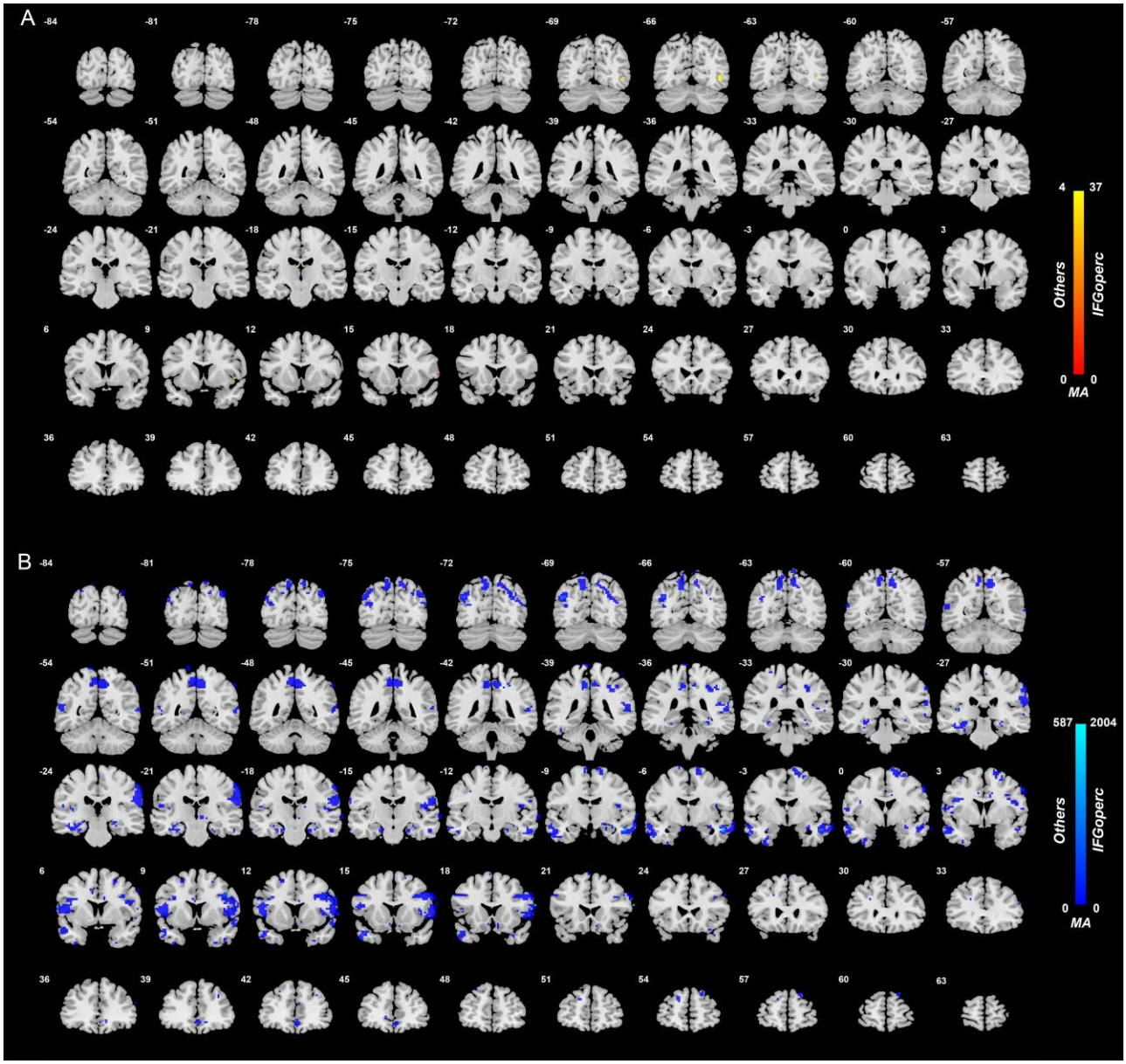

Figure S8. Comparison of differences in functional connectivity for the right (A) vs the left (B) inferior frontal gyrus in depression. Anatomical location of voxels with significantly higher functional connectivity with the inferior frontal gyrus (both triangular and opercular parts in non-medicated depression (patients - controls) obtained from the voxel-based Association Study. Red/yellow indicates voxels with higher functional connectivity in patients.

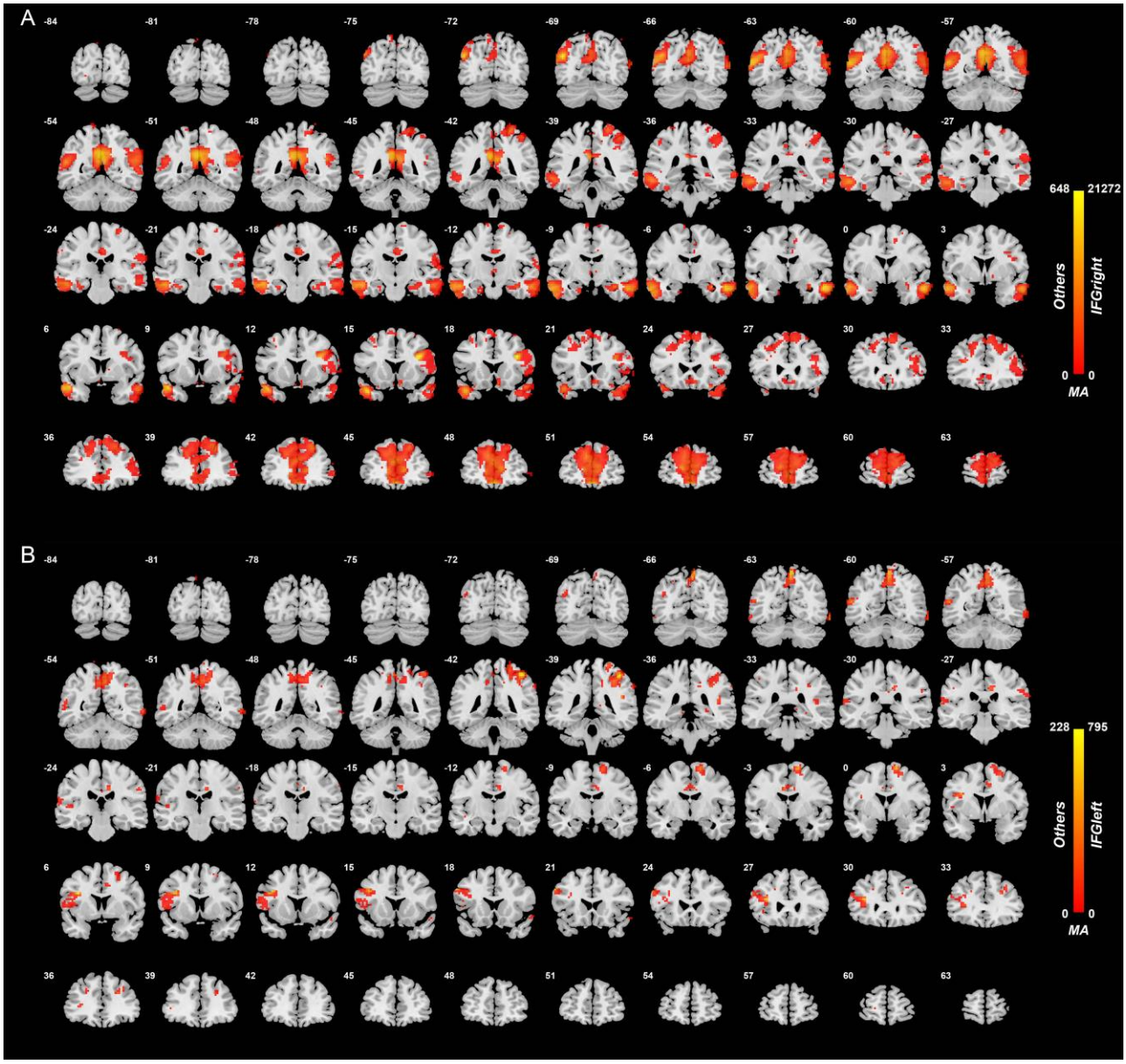

Figure S9. Functional connectivity difference for 157 medicated patients - 254 controls. B: Blue indicates voxels with lower functional connectivity in medicated depressed patients. A. Red/yellow indicates voxels with higher functional connectivity in medicated depressed patients. Voxels are shown that are significant at significantly different at $p<10^{-4}$. Voxels are included with different functional connectivities involving the medial and lateral orbitofrontal cortex and the inferior frontal gyrus pars triangularis and pas opercularis.

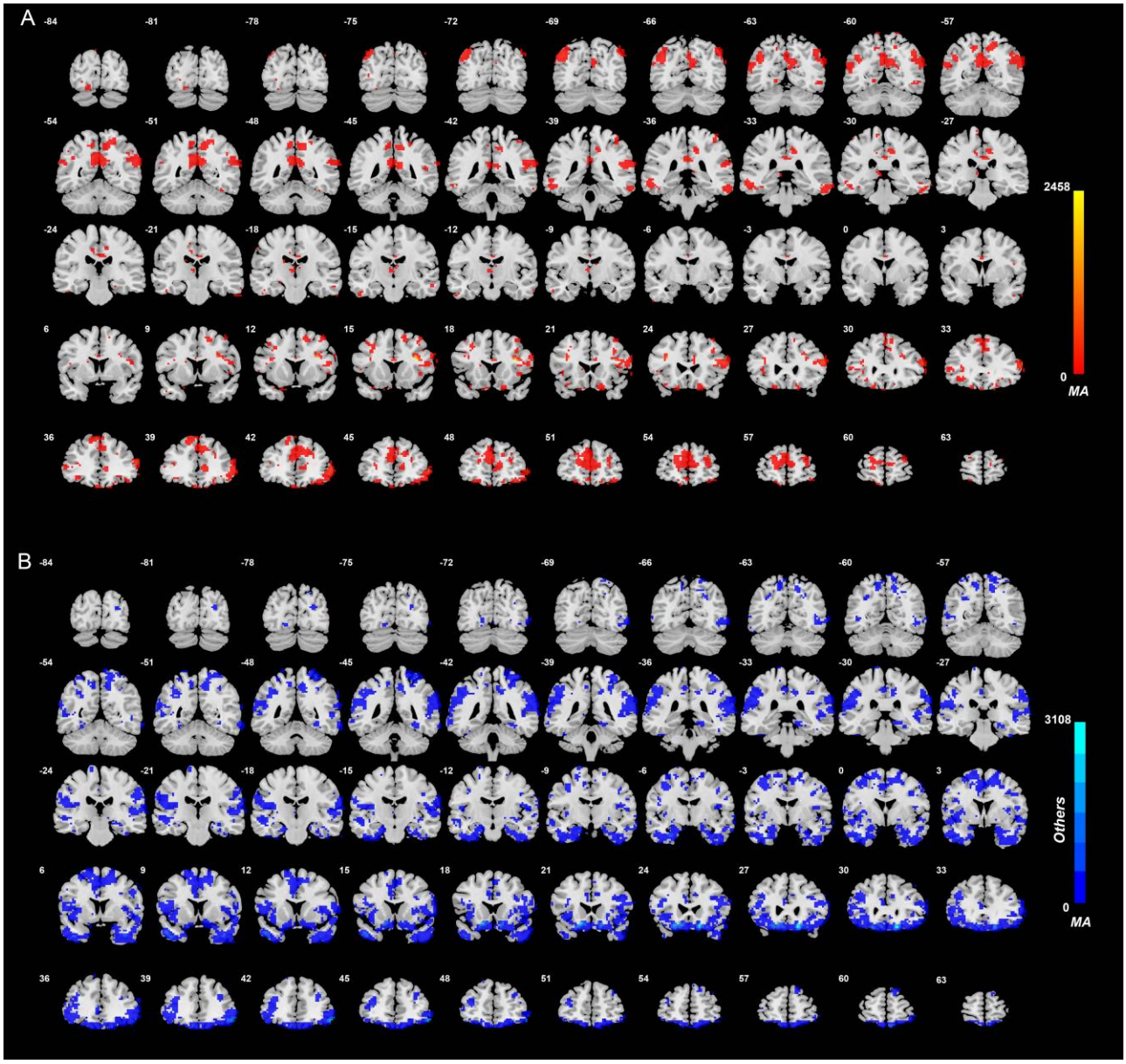

References

Beck, A. T. & Beamesderfer, A. (1974) 'Assessment of depression: the depression inventory', *Modern Problems of Pharmacopsychiatry*, **7**(0), pp. 151-169.

Cheng, W., Rolls, E. T., Qiu, J., Liu, W., Tang, Y., Huang, C. C., Wang, X., Zhang, J., Lin, W., Zheng, L., Pu, J., Tsai, S. J., Yang, A. C., Lin, C. P., Wang, F., Xie, P. & Feng, J. (2016) 'Medial reward and lateral non-reward orbitofrontal cortex circuits change in opposite directions in depression', *Brain*, **139**(Pt 12), pp. 3296-3309.

Hamilton, M. (1960) 'A rating scale for depression', *Journal of Neurology, Neurosurgery and Psychiatry*, **23**, pp. 56-62.

Rolls, E. T., Joliot, M. & Tzourio-Mazoyer, N. (2015) 'Implementation of a new parcellation of the orbitofrontal cortex in the automated anatomical labeling atlas', *Neuroimage*, **122**, pp. 1-5.